

International Journal of Intellectual Advancements and Research in Engineering Computations

SUPERPIXEL CLASSIFICATION BASED OPTIC DISC AND OPTIC CUP SEGMENTATION FOR GLAUCOMA SCREENING

^{*1}Ms.D.Sakila, ^{*2}Ms.G.Sasikala,M.E.,

ABSTRACT

Glaucoma is a chronic eye disease that leads to vision loss. As it cannot be cured, detecting the disease in time is important. Current tests using intraocular pressure (IOP) are not sensitive enough for population based glaucoma screening. Optic nerve head assessment in retinal fundus images is both more promising and superior. This paper proposes optic disc and optic cup segmentation using super pixel classification for glaucoma screening. In optic disc segmentation, histograms, and center surround statistics are used to classify each super pixel as disc or non-disc. A self-assessment reliability score is computed to evaluate the quality of the automated optic disc segmentation. For optic cup segmentation, in addition to the histograms and center surround statistics, the location information is also included into the feature space to boost the performance. The proposed segmentation methods have been evaluated in a database of 650 images with optic disc and optic cup boundaries manually marked by trained professionals. Experimental results show an average overlapping error of 9.5% and 24.1% in optic disc and optic cup segmentation, respectively. The results also show an increase in overlapping error as the reliability score is reduced, which justifies the effectiveness of the self-assessment. The segmented optic disc and optic cup are then used to compute the cup to disc ratio for glaucoma screening. Our proposed method achieves areas under curve of 0.800 and 0.822 in two data sets, which is higher than other methods. The methods can be used for segmentation and glaucoma screening. The self-assessment will be used as an indicator of cases with large errors and enhance the clinical deployment of the automatic segmentation and screening..

Index terms: Intraocular pressure, Optic disc, Segmentation, Histograms, Glaucoma screening.

I INTRODUCTION

At high risk for the disease is vital. GLAUCOMA is a chronic eye disease in which the optic nerve is progressively damaged. It is the second leading cause of blindness, and is predicted to affect around 80 million people by 2020 Progression of the disease leads to loss of vision, which occurs gradually over a long period of time. As the symptoms only occur when the disease is quite advanced, glaucoma is called the silent thief of sight. Glaucoma cannot be cured, but its progression can be slowed down by treatment. Therefore, detecting glaucoma in time is critical However, many glaucoma patients are unaware of the disease until it has reached its advanced stage. In Singapore, more than 90% of patients are unaware

that they have this condition ,. In Australia, about 50% of people with glaucoma are undiagnosed Since glaucoma progresses with few signs orsymptoms and the vision loss from glaucoma is irreversible,screening of people.

II PROBLEM AND ANALYSIS

METHODS TO DETECT GLAUCOMA

Localization and segmentation of disc are very important in many computer aided diagnosis systems, including glaucoma screening. The localization focuses on finding an disc pixel, very often the center. It has

Author for Correspondence:

^{*1}Ms.D.Sakila, PG Scholar, Department of ECE, Salem College of Engg.& Tech., Salem, Tamilnadu, India.
E-mail:sakiladhanabal@gmail.com.

^{*2}Ms.G.Sasilala M.E., Asst. Professor , Department of ECE, Salem College of Engg.& Tech., Salem, Tamilnadu, India.

been extensively studied for applications in diabetic screening. Our work focuses on the segmentation problem and the disc is located by our earlier method in ,which works well in our data set for glaucoma screening as there are few white lesions to confuse disc localization as compared to diabetic screening. The segmentation estimates the disc boundary, It relies on the edges between cup and neuroretinal rim. This method and thresholding based methods are essentially based on pallor information After obtaining the disc and cup, various features can be computed. We follow the clinical convention to compute the CDR.As mentioned in the introduction, CDR is an important indicator for glaucoma screening computed as, The computed CDR is used for glaucoma screening. When CDR is greater than a threshold, it is glaucomatous, otherwise, healthy.

MAJOR STRUCTURES OF THE OPTIC DISC.

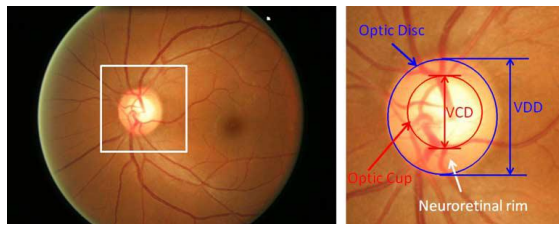


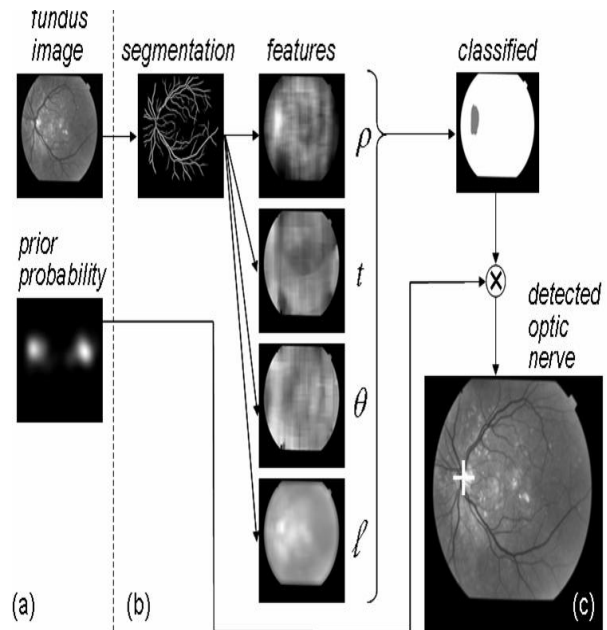
Fig 1. Major Structure of the Optic Disc

There has been some research into automatic CDR measurement from 3-D images . However, because 3-D images are not easily available, 2-D color fundus images are still referred to by most clinicians .Moreover, the high cost of obtaining 3-D images make it inappropriate for a large-scale screening program . This paper focuses on automatic glaucoma screening using CDR from 2-D fundus images. In 2-D images, the disc can be divided into two distinct zones; namely, acentral bright zone called the optic cup (in short, cup) and a peripheral region called the neuroretinalrim.The CDR is computed as the ratio of the vertical cup diameter (VCD) to vertical disc diameter (VDD) clinically. Accurate segmentations of disc and cup are essential for CDR measurement. Several methods have been proposed for automatic CDR measurement from 2-D fundus images.

DISC SEGMENTATION

One approach to address this issue is to develop inexpensive, broad-based screening programs for DR that would have a significant impact on the economic

and social consequences of vision loss from this disease. Treatment for DR is available; the challenge lies in finding a cost-effective approach with high sensitivity and specificity that can be applied to efficient, real-time population-based screening to identify those who are at risk in the early stages of the disease. The application of computer based image analysis has the potential to provide low-cost, widely distributed systems.Advances in the imaging of ocular anatomy and pathology can now provide the digital data required to diagnose and quantify specific diseases with computer-based systems, of which DR is only a subset. What is required is robust image analysis and automation to achieve productive computer-based screening of large populations. In this paper, we describe a method for the detection of the optic nerve based on segmentation of the vascular arcades. Detection of these anatomic structures is fundamental to the subsequent characterization of the normal or disease state that may exist in the retina.



2.Block diagram of Optic Disc

OPTIC DISC SEGMENT

Each image is divided into superpixels. The features computed from 18 center surround difference maps and five channel maps are used to classify the superpixels as disc or non-disc. The t th column in the feature map corresponds to the feature for the the superpixel .Localization and segmentation of disc are very important in many computer aided diagnosis

systems, including glaucoma screening. The localization focuses on finding an disc pixel, very often the center. It has been extensively studied for applications in diabetic screening. Our work focuses on the segmentation problem and the disc is located by our earlier method in ,which works well in our data set for glaucoma screening as there are few white lesions to confuse disc localization as compared to diabetic screening. The segmentation estimates the disc boundary,

OPTIC CUP SEGMENT

Detecting the cup boundary from 2-D fundus images without depth information is a challenging task as depth is the primary indicator for the cup boundary. In 2-D fundus images, one landmark to determine the cup region is the pallor, defined as the area of maximum color contrast inside the disc. Another landmark is the vessel bends at the boundary of the cup , Compared with disc segmentation, fewer methods have been proposed for cup segmentation from 2-D fundus images. Thresholding is used to determine the cup in relying on intensity difference between cup and neuroretinal rim. A level set based approach is used in .It relies on the edges between cup and neuroretinal rim. This method and thresholding based methods are essentially based on pallor information After obtaining the disc and cup, various features can be computed.We follow the clinical convention to compute the CDR.Asmentioned in the introduction, CDR is an important indicatorfor glaucoma screening computed as,The computed CDR is used for glaucoma screening. When CDR is greater than a threshold, it is glaucomatous, otherwise,healthy.

ADVANTAGES

The relative reductions of overlapping error by the proposed method are 55.0%, 39.0%, 23.0%, and 15.1% compared with the threshold, r-bend, ASM, and regression methods, respectively. Many features such as color, appearance, gist, location and texture can be extracted from superpixels for classification. The proposed methods in this paper model the disc cup boundary as an ellipse, which is an approximation of the actual boundary.

III MECHANISM AND SOLUTION

OPTIC DISC SEGMENTATION

Localization and segmentation of disc are very important in many computer aided diagnosis systems, including glaucoma screening. The localization focuses on finding an disc pixel, very often the center. It has been extensively studied for applications in diabetic screening. Our work focuses on the segmentation problem and the disc is located by our earlier method in which works well in our data set for glaucoma screening as there are few white lesions to confuse disc localization as compared to diabetic screening. The segmentation estimates the disc boundary, which is a challenging task due to blood vessel occlusions, pathological changes around disc, variable imaging conditions, etc. Some approaches have been proposed for disc segmentation, which can be generally classified as template based methods , deformable model based method, and pixel classification based methods .In circular Hough transform is used to model the disc boundary because of its computational efficiency.However, clinical studies have shown that a disc has a slightly oval shape with the vertical diameter being about 7%–10% larger than the horizontal one . Circular fitting might lead to an underestimated disc and an overestimated CDR, so ellipse fitting is often adopted for glaucoma detection Recently, the active shape model is also applied on probability maps to find the disc boundary . In addition, we also present a super pixel classification based approach using histograms to improve the initialization of the disc for deformable models. Both the template and deformable model based methods are based on the edge characteristics. The performance of these methods very much depends on the differentiation of edges from the disc and other structures, especially the PPA. The PPA region is often confused as part of disc for two reasons. It looks similar to the disc. Its crescent shape makes it from another ellipse (often stronger) to gether with the disc. To overcome the limitations of pixel classification based methods and deformable model based methods, we propose a super pixel classification based method and combine it with the deformable model based methods. Superpixels are local, coherent and provide a convenient primitive to compute local image features. They capture redundancy in the image and reduce the complexity of subsequent processing. In the proposed method, superpixel classification is used for an initialization of disc boundary and the deformable model is used to fine tune the disc boundary, i.e., a superpixel classification based disc initialization for deformable models. The flow chart of the proposed disc

segmentation method is summarized. The segmentation comprises: a superpixel generation step to divide the image into superpixels; a feature extraction step to compute features from each superpixel; a classification step each superpixel as a disc or non-disc superpixel to estimate the boundary; a deformation step using deformable models to fine tune the disc boundary.

SUPERPIXEL GENERATION

Many algorithms have been proposed for superpixel classification. They have been proved to be useful in image segmentations in various images of scene, animal, human, etc. This paper uses the simple linear iterative clustering algorithm (SLIC) to aggregate nearby pixels into superpixels in retinal fundus images. Compared with other superpixel methods, SLIC is fast, memory efficient and has excellent boundary adherence. SLIC is also simple to use with only one parameter, i.e., the number of desired superpixels. Here we give a brief introduction of the SLIC algorithm while more details of the algorithms can be found in the SLIC paper. In SLIC, initial cluster centers are sampled on a regular grid spaced by pixels apart from the image with pixels. The centers are first moved towards the lowest gradient position in a neighborhood. Clustering is then applied. For each, SLIC iteratively searches for its best matching pixel from the neighborhood around based on color and spatial proximity and then compute the new cluster center based on the found pixel. The iteration continues until the distance between the new centers and previous ones is small enough. Finally, a post processing is applied to enforce connectivity. The PPA region looks to be close to the disc. It is important to include features that reflect the difference between the PPA region and the disc region. The superpixels from the two regions often appear similar except for the texture: the PPA region contains blob-like structures while the disc region is relatively more homogeneous. The histogram of each superpixel does not work well as the texture variation in the PPA region is often from a larger area than the superpixel. This is because the superpixel often consists of a group of pixels with similar colours. Inspired by these observations, we propose center surround statistics (CSS) from superpixels as a texture feature. To compute CSS, nine spatial scale dyadic Gaussian pyramids are generated with a ratio from 1:1 (level 0) to 1:256 (level 8) as illustrated. Multiple scales are used as the scale of the blob-like structures largely vary. The dyadic Gaussian pyramid is a hierarchy of low-pass

filtered versions of an image channel, so that successive levels correspond to lower frequencies. It is accomplished by convolution with a linearly separable Gaussian filter and decimation by a factor of two.

OPTIC CUP SEGMENTATION

Detecting the cup boundary from 2-D fundus images without depth information is a challenging task as depth is the primary indicator for the cup boundary. In 2-D fundus images, one landmark to determine the cup region is the pallor, defined as the area of maximum color contrast inside the disc. Another landmark is the vessel bends at the boundary of the cup. Compared with disc segmentation, fewer methods have been proposed for cup segmentation from 2-D fundus images. Thresholding is used to determine the cup in relying on intensity difference between cup and neuroretinal rim. A level set based approach is used in. It relies on the edges between cup and neuroretinal rim. This method and thresholding based methods are essentially based on pallor information. However, in many subjects from screening data, there is no obvious pallor or edge within the disc to mark the cup boundary. The contrast between the cup and the neuroretinal rim in the two examples are much weaker than that in small vessel bends ("kinks") from the vicinity of the initial estimated cup have been used to aid the cup segmentation. The challenge is to exclude vessel bends from a non-cup boundary, especially when the initial estimation is inaccurate. A similar concept is used in to locate relevant-vessel bends ("r-bend") at the vicinity of a pallor region determined by bright pixels. This method, again, requires pallor information to find a good initial estimation of the cup boundary. Moreover, it requires at least a few bends in nasal, inferior, and superior angular of the disc for the cup boundary fitting, which is not necessarily true for many images from our experience. Xu et al. proposed a sliding window and regression based method. Although it performs better than earlier methods, the sliding window strategy requires heavy computational cost. Recently, Yin et al. developed a deformable model based method for cup. Although vessel bends are potential landmarks, they can occur at many places within the disc region and only one subset of these points defines the cup boundary. Besides the challenges to obtain these points, it is also difficult to differentiate the vessel bends that mark the cup boundary from other vessel bends without obvious pallor information.

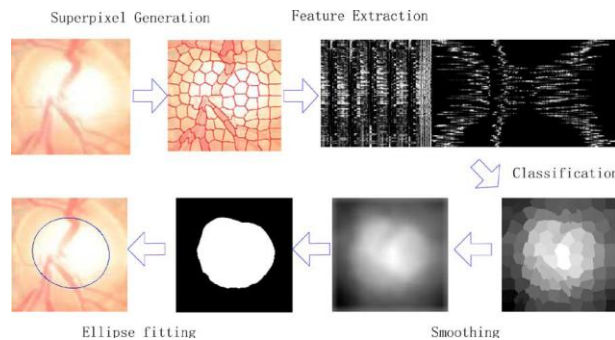


Fig 3.Result of images

EFFECTIVENESS OF THE SELF-ASSESSMENT RELIABILITY SCORE:

To show the effectiveness of the self-assessment reliability score, we compute the overlapping errors for images at different ranges of the reliability scores. Fig. 11 shows the percentage of images CHT-ASM, EHT, MDM, and the proposed method. The first row is an example without PPA where all methods work well. The second to fifth rows are examples with PPA where the proposed method outperform most of other methods. The last row is an example where all the five methods fail to find the disc boundary accurately due to an unclear boundary between PPA and disc as well as the irregular shape of disc, however, the computed reliability score by the proposed method is 0.78, which indicates a high risk of failure. Computational cost is also evaluated. It takes 10.9 s per image in a dual core 3.0 GHz PC with 3.25 GB RAM, while the EHT method takes 21.4 s, the MDM method takes 5.2 s, the CHT-ASM method takes 4.5 s, and MCV method takes 4.8 s.

DATA SETS

Our experiments uses 2326 images from 2326 different subject eyes including 650 from the Singapore Malay Eye Study (SiMES) and 1676 from the Singapore Chinese Eye Study (SCES). IOP have been measured for these eyes. Among the images, the disc and cup boundaries from 650 SiMES data set with image dimension 3072 × 2048 have been manually marked by trained professionals in previous studies for disc and cup segmentation [28], [58], [61]. The 1676 images from SCES are collected in a screening study. There are two sizes: 3504 × 2336 and 3888 × 2592. All the SCES images are resized to be the same size as the SiMES data set, for convenience. The disc localization method in [25] is then used to locate the disc and determine an 800

800 region of interest for disc and cup segmentation. It locate disc correctly in all 650 SiMES images. In SCES, it fails in four of 1676 images been some research into automatic CDR measurement from 3-D images [14]–[17]. However, because 3-D images are not easily available, 2-D color fundus images are still referred to by most clinicians [8], [14]. Moreover, the high cost of obtaining 3-D images make it inappropriate for a large-scale screening program [8]. This paper focuses on automatic glaucoma screening using CDR from 2-D fundus images. The optic nerve head or the optic disc (in short, disc) is the location where ganglion cell axons exit the eye to form the optic nerve, through which visual information of the photo-receptors is transmitted to the brain. In 2-D images, the disc can be divided into two distinct zones; namely, a central bright zone called the optic cup (in short, cup) and a peripheral region called the neuroretinal rim. Fig. 1 shows the major structures of the disc. The CDR is computed as the ratio of the vertical cup diameter (VCD) to vertical disc diameter (VDD) clinically. Accurate segmentations of disc and cup are essential for CDR measurement. Several methods [8], [18]–[21] have been proposed for automatic CDR measurement from 2-D fundus images. This paper proposes superpixel classification based disc and cup segmentations for glaucoma screening. A similar concept has been used for vessel segmentation [22]. We compute center surround statistics from superpixels and unify them with histograms for disc and cup segmentation. We incorporate prior knowledge of the cup by including location information for cup segmentation. Based on the segmented disc and cup, CDR is computed for glaucoma screening. In addition, the proposed method computes a self-assessment reliability score for its disc segmentation result. Self-assessment is an important issue that has previously seldom been discussed in disc segmentation. In practice, an automated segmentation method might work well for most images while working poorly for the rest. Therefore, it is important to have self-assessment where users are warned of cases with potentially large errors. The paper is organized as follows.

In Section II, we introduce superpixel classification based OD segmentation including the generation of superpixels, the extraction of features from superpixels for the classification and the computation of the self-

assessment reliability score. Section III introduces super-pixel classification based cup segmentation, where the procedure is similar to that in disc segmentation. Section IV shows the experimental results including the accuracy for disc and cup segmentation as well as glaucoma screening. Discussions and conclusions are presented in final section. We present a super pixel classification based method for cup segmentation that incorporates prior knowledge into the training of super pixel classification instead of relying on vessel bends.

CSS responds to blobs and provides better differentiation between PPA and discs compared with histograms. Histograms with the contrast enhancement overcome the limitation of CSS due to contrast variations. Reliability score is an important indicator of the automated results. From our experience, disc segmentations with is likely to indicate good cases. For lower ones, it is likely that the results are inaccurate, even though the deformation in the last step might still find a good result in some situations. It is important to have a good disc segmentation because the CDR computed from a wrong disc is not very meaningful for doctors. In cup segmentation, the benefit of CSS is even larger than that in disc segmentation, because the color change from cup to neuroretinal rim is much smaller. Therefore, the uneven illumination becomes a large noise affecting the cup segmentation. The CSS computed from the center surround difference is less sensitive, and thereby improves the result. It is important to point out that the proposed superpixel classification is used as an initialization for deformable models. We have demonstrated that, by replacing circular Hough transform based initialization with the proposed one for active shape model, we are able to improve the disc segmentation.

IV CONCLUSION

One limitation of the proposed cup segmentation is that the trained classifier is slightly dominated by cups with medium sizes, so the proposed method underestimates the very large cups, while overestimating the very small cups when pallor is not obvious. This is partly due to the use of the location feature. However, the advantage is that helps to avoid very bad results. Both the cup segmentation accuracy and glaucoma screening

accuracy show improvement by including in the feature space. One possible solution to overcome this limitation is to collect more samples with very small and very large cups for training. Another possible solution is to adopt multiple kernels. This paper concatenates the three types of features from different sources. In future work, multiple kernel learning [65] will be used for enhancement. A third possible solution is to use vessel bends to correct the bias in current cup segmentation. For example, we can obtain the vessel bends as in [57], [8] from the vicinity of the current cup boundary to fine-tune the cup boundary. As it requires some heuristics in vessel tracking and bending detection, a robust algorithm is important for future development. Despite the bias, the obtained CDRs for very large cups are still high and the CDRs for very small cups are still small, so the proposed method achieves high classification accuracy when differentiating glaucomatous subjects from healthy ones.

One limitation of the proposed cup segmentation is that the trained classifier is slightly dominated by cups with medium sizes, so the proposed method underestimates the very large cups, while overestimating the very small cups when pallor is not obvious. This is partly due to the use of the location feature. However, the advantage is that helps to avoid very bad results. Both the cup segmentation accuracy and glaucoma screening accuracy show improvement by including in the feature space. One possible solution to overcome this limitation is to collect more samples with very small and very large cups for training. Another possible solution is to adopt multiple kernels. This paper concatenates the three types of features from different sources. In future work, multiple kernel learning [65] will be used for enhancement. A third possible solution is to use vessel bends to correct the bias in current cup segmentation. For example, we can obtain the vessel bends as in [57], [8] from the vicinity of the current cup boundary to fine-tune the cup boundary. As it requires some heuristics in vessel tracking and bending detection, a robust algorithm is important for future development.

REFERENCE

- [1]. Abramoff M. D., Alward W. L. M., Greenlee E. C., Shuba L., Kim C. Y., Fingert J. H., and Kwon Y. H., "Automated segmentation

- of the optic disc from stereo color photographs using physiologically plausible features," *Invest. Ophthalmol. Vis. Sci.*, vol. 48, pp. 1665–1673, 2007.
- [2]. Centre Eye Res. Australia, Tunnel vision: The economic impact of primary open angle glaucoma 2008 [Online]. Available: <http://nla.gov.au/nla.arc-86954>
- [3]. Jonas J. B., Fernandez M. C., and Naumann G. O., "Glaucomatous parapapillary atrophy occurrence and correlations," *Arch. Ophthalmol.*, vol. 110, pp. 214–222, 1992
- [4]. Joshi G. D., Sivaswamy J., and Krishnadas S. R., "Optic disk and cup segmentation from monocular color retinal images for glaucoma assessment," *IEEE Trans. Med. Imag.*, vol. 30, no. 6, pp. 1192–1205, Jun. 2011.
- [5]. Xu, O. Chutatape, E. Sung, C. Zheng, and P. C. T. Kuan, "Optic disk feature extraction via modified deformable model technique for glaucoma analysis," *Pattern Recognit.*, vol. 40, pp. 2063–2076, 2007.
- [6]. R. Bock, J. Meier, L. G. Nyl, and G. Michelson, "Glaucoma risk index: Automated glaucoma detection from color fundus images," *Med. Image Anal.*, vol. 14, pp. 471–481, 2010.
- [7]. segmentation from monocular color retinal images for glaucoma assessment," *IEEE Trans. Med. Imag.*, vol. 30, no. 6, pp. 1192–1205, Jun. 2011.
- [8]. T. Damms and F. Dannheim, "Sensitivity and specificity of optic disc parameters in chronic glaucoma," *Invest. Ophth. Vis. Sci.*, vol. 34, pp. 2246–2250, 1999
- [9]. D. Michael and O. D. Hancox, "Optic disc size, an important consideration in the glaucoma evaluation," *Clin. Eye Vis. Care*, vol. 11, pp. 59–62, 1999.
- [10]. N. Harizman, C. Oliveira, A. Chiang, C. Tello, M. Marmor, R.
- [11]. Ritch, and J. M. Liebmann, "The ISNT rule and differentiation of normal from glaucomatous eyes," *Arch. Ophthalmol.*, vol. 124, pp. 1579–1583, 2006.
- [12]. J. B. Jonas, M. C. Fernandez, and G. O. Naumann, "Glaucomatous parapapillary atrophy occurrence and correlations," *Arch. Ophthalmol.*, vol. 110, pp. 214–222, 1992.
- [13]. R. R. Allingham, K. F. Damji, S. Freedman, S. E. Moroi, and G. Shafranov, *Shields' Textbook of Glaucoma*, 5th ed. Philadelphia, PA: Lippincott Williams Wilkins, 2005.
- [14]. J. Xu, O. Chutatape, E. Sung, C. Zheng, and P. C. T. Kuan, "Optic disk feature extraction via modified deformable model technique for glaucoma analysis," *Pattern Recognit.*, vol. 40, pp. 2063–2076, 2007.